

The Journal of Bone and Joint Surgery

American Volume

VOLUME 48-A, No. 2

MARCH 1966

The Carpal-Tunnel Syndrome

SEVENTEEN YEARS' EXPERIENCE IN DIAGNOSIS AND TREATMENT
OF SIX HUNDRED FIFTY-FOUR HANDS *

BY GEORGE S. PHALEN, M.D.†, CLEVELAND, OHIO

From the Department of Orthopedic Surgery, The Cleveland Clinic Foundation, Cleveland

Carpal-tunnel syndrome, the name now commonly applied to compression neuropathy of the median nerve at the wrist, is the most common cause of burning pain, numbness, and tingling in the thumb, index and long fingers, and in the lateral half of the palm. Progressive atrophy of the thenar muscles, with or without pain and numbness in the median-nerve distribution in the hand, may also be caused by compression of the median nerve beneath the transverse carpal ligament.

The median nerve passes directly beneath the transverse carpal ligament and lies superficial to the nine flexor tendons of the digits within the close confines of the carpal tunnel. It is at this level that the median nerve is so easily compressed by any condition that increases the volume of the structures within the carpal tunnel. Even a slight swelling of the synovial sheath of the flexor tendons may be sufficient to force the median nerve up against the firm, inelastic transverse carpal ligament, causing motor and sensory changes in the structures supplied by the distal portion of the nerve. The median nerve may anastomose to a variable extent with the ulnar and even the radial nerves; these connections explain the frequent variability both in motor and in sensory findings in median-nerve palsy.

The median nerve may be directly damaged or secondarily compressed by an acute or old traumatic lesion of the carpus. Post-traumatic compression of the median nerve may be minimum at first and then gradually progress to a complete paralysis. Such a syndrome could be aptly termed *tardy median-nerve palsy* because of its similarity to the much more common *tardy ulnar-nerve palsy*. The terms *tardy median-nerve palsy* and *carpal-tunnel syndrome* should not be used interchangeably, because the former term implies a traumatic origin and the majority of patients with carpal-tunnel syndrome give no history of antecedent injury to the forearm, wrist, or hand.

In 1854 Paget discussed compression of the median nerve at the wrist secondary to trauma. In 1913, Marie and Foix, at the autopsy of a patient with advanced atrophy of the thenar muscles but no history of injury, demonstrated neuromata in both median nerves just proximal to the transverse carpal ligament. They were the first to recommend decompression of the median nerve by sectioning the transverse carpal ligament in order to prevent paralysis of the thenar muscles. Moersch, in

* Read at the Annual Meeting of the American Society for Surgery of the Hand, New York, N. Y., January 8, 1965.

† 2020 East 93rd Street, Cleveland, Ohio 44106.

1938, also recommended section of the transverse carpal ligament in a patient with bilateral median neuritis, but no operation was performed. In 1946, Cannon and Love reported on thirty-eight cases of tardy median-nerve palsy, in nine of which the patient was treated by section of the transverse carpal ligament. Three of these nine patients had no definite history of antecedent trauma. Brain, Wright, and Wilkinson, in 1947, first focused attention on spontaneous compression of the median nerve in the carpal tunnel by their detailed report of six patients treated successfully by sectioning the transverse carpal ligament.

In November 1947, I made my first diagnosis of carpal-tunnel syndrome and, in 1949, reported on four patients, three of whom were treated surgically for this condition. Seventy-one patients were also reported on in 1956. The present paper reports a study of the carpal-tunnel syndrome in 654 hands of 439 patients seen at the Cleveland Clinic before August 1, 1964. Since 1960, approximately fifty patients a year have been treated for carpal-tunnel syndrome in this clinic.

Diagnosis

The diagnosis of carpal-tunnel syndrome must be considered in any patient who has hypesthesia or paresthesia in the distribution of the median nerve in the hand or in any patient who has weakness or paralysis of the abductor pollicis brevis or opponens pollicis. Women are much more apt to have the syndrome than men; in the Cleveland Clinic series 293 of the 439 patients (67 per cent) were women.

More than half of the patients were between forty and sixty years of age (Table I). The youngest patient was twenty and the oldest eighty-seven years old.

TABLE I
AGE RANGE OF 439 PATIENTS WITH CARPAL-TUNNEL SYNDROME

Years	No. of Patients
20 to 29	13
30 to 39	48
40 to 49	111
50 to 59	132
60 to 69	85
70 to 79	41
80 to 89	6
Not recorded	3
Total	439

The usual history is that of progressive weakness and clumsiness in the hands associated with hypesthesia and tingling in the distribution of the median nerve distal to the wrist joint. Although mild symptoms may have been present for many years, the more severe symptoms, for which the patient seeks medical attention, may have developed quite recently, often associated with a sudden change to more strenuous manual labor. The symptoms are usually bilateral and are worse in the dominant hand.

In the 654 hands in this series, symptoms had been present for less than six months in 197 (32 per cent), from six months to two years in 150 (24 per cent), from two to ten years in 176 (28 per cent), from ten to twenty years in fifty-seven (9 per cent), and for more than twenty years in thirty-eight (6 per cent). The duration of symptoms in thirty-six hands was not recorded.

Strenuous use of the hand almost always aggravates the symptoms, although the increased numbness and tingling in the fingers may not be noted until the hand has been resting for several hours after the activity.

Pain at night, often severe enough to prevent sleep, is a frequent complaint. The patient is awakened by burning pain in the thumb and index and long fingers. Hanging the hand out of bed, exercising the fingers, or vigorous shaking of the hand often cause prompt lessening of pain. Although pain may be referred to the forearm, elbow, or shoulder, there are never any subjective or objective sensory changes proximal to the wrist joint. Numbness and tingling in the hand is usually aggravated by a sustained grasp, such as holding a knife or broom, driving a car, or turning a lever.

A sensory disturbance in the distribution of the median nerve distal to the wrist joint is the most constant clinical finding. At the time of examination only fifty-four hands (8 per cent) in this series were reported to show no demonstrable loss of sensation.

Hypesthesia was demonstrated in 517 hands (79 per cent). The hypesthesia may be minimum, usually in the distal phalanx of the long finger; but the patient will readily point out the portion of the hand in which paresthesia and numbness occur after strenuous use of the hand, and this area will invariably coincide with the sensory distribution of the median nerve. Often the patient insists that "the whole hand gets numb and tingly at night," but careful interrogation will bring out the fact that the little finger is spared. Since the little finger receives all of its sensory supply from the ulnar nerve, this digit is never involved in the true carpal-tunnel syndrome. All of the fingers may feel stiff and swollen, especially on arising in the morning, but these symptoms improve or disappear with resumption of active use of the hands.

Hyperesthesia to pinprick in the distribution of the median nerve in the hand,

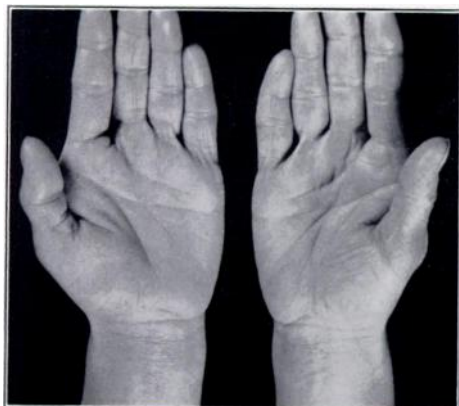


FIG. 1-A

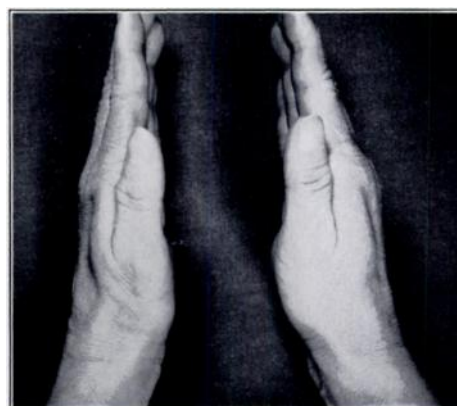

FIG. 1-B

Fig. 1-A: Hands of a woman, forty-six years old, with bilateral carpal-tunnel syndrome of two years' duration. The patient had not observed the moderate thenar atrophy of her left hand.

Fig. 1-B: The thenar atrophy of the left hand becomes much more obvious when the thenar eminences are compared in profile.

comparing the patient's reaction to pinprick here with that to pinprick on the normal little finger, was present in twenty-nine hands (4.6 per cent). Paresthesia alone in the same distribution was recorded as being present in thirty-nine hands (6 per cent). The records failed to describe the sensory findings in fifteen hands.

Thenar atrophy almost always is preceded by hypesthesia in the median distribution for many months or many years. Atrophy of the opponens pollicis, abductor pollicis brevis, and flexor pollicis brevis was observed in various degrees in 261 (41 per cent) of the hands included in this series. Many patients note weakness and clumsiness in their thumbs, but are unaware of the thenar-muscle atrophy until the examining physician shows it to them. The thenar atrophy may not be noticed when the examiner looks down on the palm of the hand, but it will be readily appreciated

when the profiles of the thenar eminences are compared (Figs. 1-A and 1-B). The abductor pollicis brevis has been described as the muscle most often initially involved in this syndrome, and weakness in this muscle is an early sign of median-nerve compression. Testing of this muscle was not recorded in a sufficiently large number of patients in this series to draw firm conclusions as to the efficacy of this test as an early diagnostic aid.

No atrophy was present in 374 hands and there was no record of the presence or absence of atrophy in nineteen hands in this series.

Tinel's sign, a tingling sensation radiating out into the hand produced by light percussion over the median nerve at the wrist, is a valuable sign in the diagnosis of carpal-tunnel syndrome. In 452 (73 per cent) of the hands in this series Tinel's sign was present; in 169 it was absent; in thirty-three there was no note regarding Tinel's sign.

In performing the so-called wrist-flexion test, the patient is asked to hold the forearms vertically and to allow both hands to drop into complete flexion at the

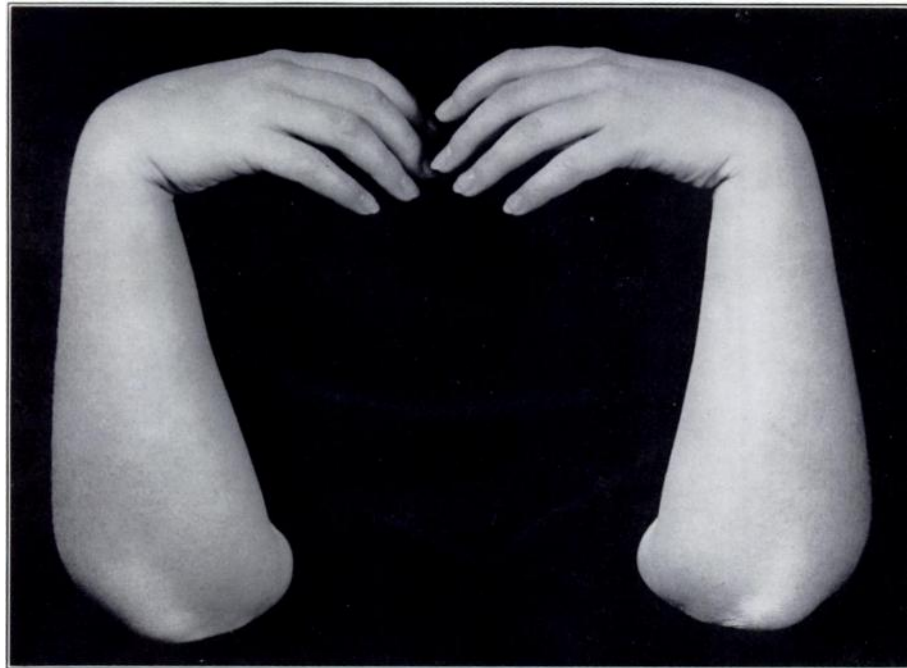

FIG. 2

The wrist-flexion test is positive when numbness and paresthesia in the median-nerve distribution in the hand are reproduced or exaggerated by holding the wrists in complete flexion for from thirty to sixty seconds.

wrist for approximately one minute (Fig. 2). In this position the median nerve is squeezed between the proximal edge of the transverse carpal ligament and the adjacent flexor tendons and radius. Maintaining this position for a long time eventually causes numbness and tingling over the distribution of the median nerve in the normal hand. However, when the median nerve is already somewhat compressed within the carpal tunnel, further compression by this maneuver causes almost immediate aggravation of the numbness and paresthesia in the fingers. The patient often volunteers "This is the pain that wakes me up at night." In interpreting this wrist-flexion test, one must remember that the test will not be positive if there is already an advanced degree of sensory loss in the hand. For 139 hands in this series, the wrist-flexion test was not performed or was not recorded. For the remaining 515, the test was positive

in 380 (74 per cent) and negative in 135. In the wrists treated surgically, no explanation was found at operation for the presence or absence of a positive wrist-flexion test.

Sustained extension of the wrist may also aggravate the symptoms of carpal-tunnel syndrome, but I have not found this to be a consistently reliable diagnostic sign. Firm pressure of the examiner's thumb over the median nerve at the wrist may also increase the pain, numbness, and tingling in the distribution of the median nerve. This test is seldom positive, however, until there has been sufficient pressure on the nerve in the tunnel to cause the nerve to become swollen proximal to the ligament. When this occurs, there is seldom any question about the correct diagnosis.

Another diagnostic test³ is the production of increased pain and paresthesia in the distribution of the median nerve by inflating a pneumatic cuff on the arm to a pressure above the systolic pressure for a minute or two. The irritated and compressed portion of the median nerve in the carpal tunnel is more susceptible to ischemia than the normal nerve. However, some numbness and tingling are produced in the fingers of a normal hand when a tourniquet is applied to the arm. I have, therefore, found the results of the tourniquet test difficult to evaluate, especially in a mild carpal-tunnel syndrome. Although it was not possible to compare the results of the wrist-flexion and tourniquet tests in this series, it is my impression that the wrist-flexion test is much more valuable.

Without a history of trauma to the wrist, one may anticipate that roentgenograms will disclose no abnormality in the osseous contour of the carpal tunnel. The patient who is to be operated on, however, should have a roentgenographic evaluation.

Swelling on the volar aspect of the forearm just proximal to the wrist joint is a rather common finding in patients with the carpal-tunnel syndrome. When the condition is unilateral, this swelling may be much more obvious than in the bilateral cases. Patients with carpal-tunnel syndrome caused by rheumatoid arthritis almost always have swelling, caused by thickening of the flexor synovialis. Swelling on the volar aspect of the forearm proximal to the wrist joint was recorded as being present in sixty-nine wrists, but there were probably minor degrees of swelling in many more wrists. Swelling of the entire hand or of the fingers was recorded as being present in fifty-one wrists.

In sixteen wrists there was a ganglion on the volar aspect, and in three wrists a ganglion was present on the dorsal aspect. No conclusion as to the causal relationship between a ganglion of the wrist and the carpal-tunnel syndrome may be drawn from this series. Two of the wrists with a ganglion were operated on, and the ganglion was found to be occupying some space within the carpal tunnel. In both instances the ganglion could have been causing some pressure on the median nerve, and symptoms were relieved by removal of the ganglion and section of the carpal ligament.

Electrodiagnostic procedures may be helpful when the diagnosis is in doubt. Conduction time for the motor fibers is determined by stimulating the median nerve with a bipolar electrode at the proximal flexion crease of the wrist, and recording the time required for the appearance of the muscle action potential of the *opponens pollicis* or the *abductor pollicis brevis*. Normally the conduction delay, or latency, is less than five milliseconds; but, in patients with carpal-tunnel syndrome, the conduction delay may be as long as twenty milliseconds. In a series of thirty-eight patients with the carpal-tunnel syndrome, Johnson and associates found a mean conduction delay of 8.4 milliseconds. I have not employed this procedure in many patients, because the clinical assessment was sufficient to make an accurate diagnosis. Electromyography may be of value in the differential diagnosis between carpal-tunnel syndrome and irritation of the sixth and seventh cervical-nerve roots, especially when the sen-

sory pattern in the hand and the rest of the extremity is equivocal or when there is pain referred into the forearm and shoulder from a median nerve compressed in the carpal tunnel. Nerve conduction time may also be useful in demonstrating objective evidence of postoperative improvement in a patient who maintains that he is no better after surgical treatment. One must remember, however, that median-nerve conduction time of motor impulses may be normal in the presence of an obvious carpal-tunnel syndrome or may be slow in a normal patient.

An accurate diagnosis of carpal-tunnel syndrome may be made if the wrist-flexion test is positive, Tinel's sign is present over the median nerve at the wrist, and all objective sensory findings are strictly limited to the distribution of the median nerve distal to the wrist. These are the three most reliable clinical findings, and in almost every patient found to have the syndrome at least two of the three findings are present. In addition, partial atrophy of the thenar muscles will be present in about half of the cases.

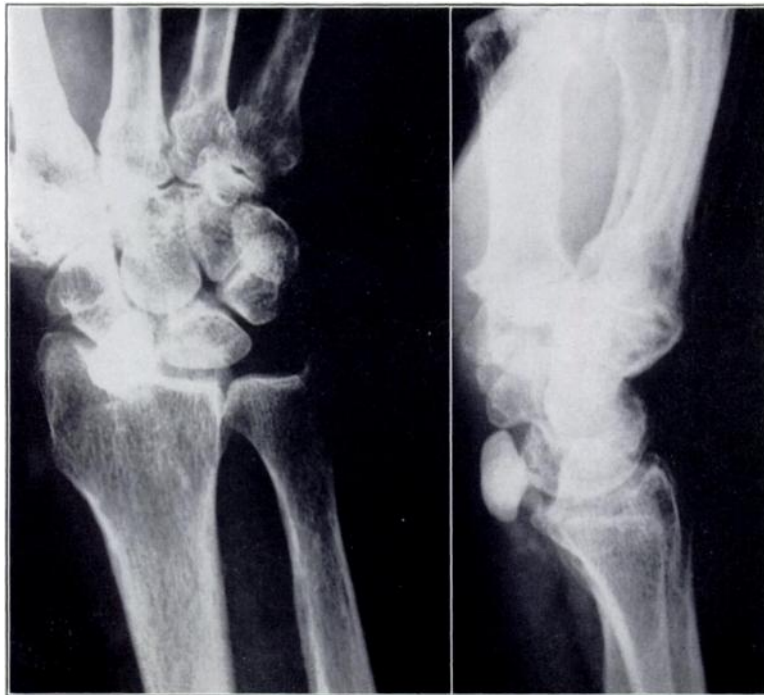

FIG. 3

Roentgenograms of the wrist showing evidence of a large calcific deposit within the carpal tunnel, producing an acute carpal-tunnel syndrome. (Courtesy of John R. Stacy, M. D., Oklahoma City, Oklahoma.)

Pathogenesis

Thickening or fibrosis of the flexor synovialis within the carpal tunnel was the most common cause of the syndrome, being found in 203 of 212 wrists. Biopsy specimens of the flexor synovialis were taken from 181 of the 212 wrists treated surgically. Pathological examination revealed chronic fibrosis or thickening of the synovialis in ninety-one specimens, chronic inflammation compatible with a diagnosis of rheumatoid synovitis in sixty-four specimens, and no pathological change in twenty-six. Although the exact nature of the synovial thickening could not be demonstrated, it is believed that it must be associated with some rheumatic process in the majority of the cases. The improvement noted in many patients after the injection of

steroid preparations into the carpal tunnel is consistent with a rheumatic origin of the tenosynovitis. Furthermore, many patients noted transient stiffness and swelling of the small joints of their hands, symptoms thought to result from peri-arthritis.

Some authors^{3,7} have cited ischemia of the median nerve as the cause of carpal-tunnel syndrome. I believe that localized ischemia of the nerve may be associated with compression of the nerve within the carpal tunnel. The rapid disappearance of paresthesia and pain after section of the transverse carpal ligament is consistent with temporary ischemia. At operation the vasa nervorum of many median nerves were seen to disappear abruptly at the proximal edge of the carpal ligament. It was also noted that after division of the carpal ligament and release of the tourniquet, engorgement of the nerve would develop but this engorgement would stop abruptly at the level of the proximal edge of the ligament—the site of major compression.

In cases of long-continued severe compression, the ischemic changes in the nerve may be permanent. Tanzer found vasomotor imbalance to be a prominent feature in fifteen of twenty-five hands with carpal-tunnel syndrome, as manifested by significant sensitivity to cold. Since the median nerve carries with it most of the sympathetic nerve supply of the hand, it seems logical to anticipate certain vasomotor changes arising from irritation or compression of the nerve.

Thickening of the transverse carpal ligament itself may be sufficient to compress the median nerve in certain systemic disorders, such as acromegaly, pleon-osteosis, and myxedema. Although there was some slight variation in the thickness of the transverse carpal ligament in the wrists that were operated on, in no instance was it apparent to the surgeon that the ligament itself was the primary cause of the median-nerve compression. Several biopsies were made of the transverse carpal ligament and these revealed no pathological changes.

Any condition that increases the volume of the contents of the carpal tunnel obviously tends to compress the median nerve. Benign tumors, such as lipomata, hemangiomas, and ganglia may encroach upon the carpal tunnel. In this series one hemangioma and two ganglia were found to be causing compression of the median nerve. Deposits of calcium and gouty tophi may also be of sufficient magnitude to produce such pressure (Fig. 3). Amyloid disease, as is often seen in patients with multiple myeloma, may produce the syndrome as the result of thickening of the flexor synovialis and transverse carpal ligament; compression of the median nerve may even be the initial manifestation of the systemic disease^{4,5}. In this series, there were four patients with multiple myeloma; one underwent surgical treatment. Special stains on sections of the flexor synovialis from this patient showed amyloid infiltration.

The fact that the majority of patients with carpal-tunnel syndrome are women at or near the menopause suggests that the soft tissues about the wrist may be affected in some manner by hormonal changes. Some clinicians^{14,15} have reported at least temporary improvement after the administration of estrogens. Others have found estrogens to be ineffective. At the Cleveland Clinic we have not employed hormonal therapy. However, we have noted the onset or aggravation of symptoms during pregnancy and believe this may be associated with retention of fluid in the tissues about the wrist or perhaps increase of adipose tissue in the carpal tunnel. Chlorothiazide has been effective in controlling the symptoms occasionally, but I have not employed this medication in enough patients to evaluate its efficacy.

Congenital anomalies in the region of the carpal canal have frequently been reported as a cause of median-nerve compression, including distal prolongation of the muscle bellies of the flexor digitorum sublimis and anomalous muscles¹⁶. Because most of the operations I performed were carried out through transverse incisions, I could not search thoroughly for congenital anomalies in the carpal tunnel. It is my

impression, however, that a congenital anomaly is rarely the primary cause of compression.

Based on clinical observations, it is my strong impression that venous stasis is a factor in the production of symptoms. Vasodilatation and venous stasis accompanying sleep and inactivity could well explain the night pain. With engorgement of vessels in the flexor synovialis, increasing the volume of the contents of the carpal tunnel, pressure is applied to the median nerve. Active motion of the flexor tendons could then relieve the pain by mechanically decreasing venous engorgement within the carpal tunnel.

Although any type of trauma which alters the normal contour of the carpal tunnel or damages the median nerve or flexor tendons may produce the syndrome, the findings in this study indicated that local trauma to the wrist was seldom an etiological factor. Only seventy patients (16 per cent) gave a history of wrist injury which could be considered a possible cause of median neuropathy (Table II). Only twenty-

TABLE II
TRAUMA PRECEDING ONSET OF SYMPTOMS IN SEVENTY PATIENTS WITH CARPAL-TUNNEL SYNDROME

Type of Injury	No. of Patients		
	Total	Men	Women
Fractures	27		
Distal end of radius (Colles)		6	7
Carpal bone		6	6
Metacarpal		1	0
Radius and ulna, lower third		0	1
Sprain of wrist	10	5	5
Direct blow to hand or wrist	9	6	3
Laceration of wrist	2	2	0
Operation for flexor graft	1	1	0
Recent excessive use of hands	21	11	10
Total	70	38	32

seven had fractures: thirteen, Colles' fracture; twelve, fractures of one or more carpal bones; one, a fracture through the lower third of the forearm bones; and one, a fracture of the metacarpals. If recent excessive use of the hands was excluded as a possible traumatic cause of the syndrome, only 11 per cent of the patients in the series could be classified as having post-traumatic carpal-tunnel syndrome. Men and women were equally represented in the group with post-traumatic symptoms. The position of acute volar flexion and ulnar deviation of the hand at the wrist (Cotton-Loder position) should be condemned in the treatment of Colles' fracture because of the danger of median-nerve compression. Malunited fractures or fractures with excessive new-bone formation may cause compression of the median nerve. Carpal dislocations, acute sprains of the wrist, or direct blows to the wrist may also traumatize the median nerve. Irregularity of the carpal bones caused by old fractures and advanced post-traumatic arthritis of the wrist have also been reported² as causes of the syndrome.

Recent excessive use of the hands was thought to be an etiological factor in only twenty-one of the cases in this series. Brain and associates demonstrated that pressure within the carpal tunnel was three times greater with the wrist extended than with the wrist flexed and concluded that sustained vigorous work with the wrist extended might initiate the syndrome. Tanzer showed that similar increases in pressure within the proximal portion of the carpal tunnel may be produced by both flexion and extension of the wrist; he also demonstrated that the median nerve is compressed against the transverse carpal ligament by simultaneous and forceful flexion of the

TABLE III
OCCUPATION OF PATIENTS WITH CARPAL-TUNNEL SYNDROME

Type of Occupation	No. of Patients		
	Total	Men	Women
Housekeeper or cook	210	3	207
Laborer	26	25	1
Assembly work	18	10	8
Salesman, saleswoman	18	10	8
Clerk, accountant	16	5	11
Mechanic, machinist	15	15	0
Executive	11	11	0
Teacher	9	0	9
Secretary	8	0	8
Nurse	8	0	8
Physician	6	6	0
Dentist	1	1	0
Other professions	8	8	0
Carpenter, painter, electrician	7	7	0
Waitress	5	0	5
Barber, beautician	4	1	3
Farmer	4	4	0
Draftsman	2	2	0
Telephone operator	2	0	2
Dressmaker, tailor	2	1	1
Florist	2	1	1
Dry cleaner	2	1	1
Professional golfer	1	1	0
Retired	14	12	2
No excessive use of hands	29	20	9
Not recorded	11	6	5
Total	439	150	289

wrist and fingers. Occupations that require active finger flexion with the wrist flexed should certainly predispose to a carpal-tunnel syndrome, but fortunately such occupations are not common.

The common, typical, carpal-tunnel syndrome—spontaneous compression neuropathy of the median nerve in the carpal tunnel—is not an occupational disease. A chronic tenosynovitis of the flexor tendons in the carpal tunnel might result from prolonged excessive forceful grasping movements, but such a tenosynovitis is not a common finding in industrial workers. Most patients with a carpal-tunnel syndrome have an aggravation of symptoms after strenuous use of the hands, and the symptoms are usually worse in the dominant hand. In this series, there were sixty-five patients with symptoms limited to the left hand, but only five of them were left-handed. The occupations of the patients in the series are listed in Table III. Men certainly subject their hands to more trauma than do women, but men contributed only 33 per cent of all cases in this series. Excluding the seventy cases directly associated with trauma, men comprised only 29 per cent of the remaining cases. An occupation may aggravate but seldom produces a carpal-tunnel syndrome.

Evidently many persons tend to keep their wrists flexed during sleep. Complete flexion of the wrist maintained while sleeping most certainly produces some compression of the median nerve in the normal wrist. This so-called waking numbness develops in a much shorter period and produces more severe symptoms in a wrist with a mild carpal-tunnel syndrome than in a normal wrist. It is recommended that wrist splints be worn by persons who constantly keep their wrists flexed during sleep to prevent compression of the median nerve.

I agree with Tanzer that there probably is some sort of predisposition to the

TABLE IV
OTHER DISEASES PRESENT WITH CARPAL-TUNNEL SYNDROME

Name of Disease	No. of Patients		
	Total	Men	Women
Trigger finger or thumb	34	8	26
Diabetes mellitus	33	9	24
Rheumatoid arthritis	49	11	38
Periarthritis of shoulder	28	8	20
Tennis elbow	21	4	17
Hypertrophic arthritis carpus	12	3	9
de Quervain's	10	1	9
Dupuytren's	8	4	4
Thoracic outlet syndrome	5	2	3
Lupus erythematosus	4	1	3
Multiple myeloma	4	4	0
Calcific tendinitis at wrist	3	0	3
Psoriasis	3	1	2
Myxedema	3	2	1
Alcoholic neuropathy	3	2	1
Gout	2	2	0
Tietze's	2	1	1
Dyschondroplasia	2	2	0
Primary amyloidosis	1	0	1
Pernicious anemia	1	0	1
Leukemia	1	1	0
Multiple sclerosis	1	1	0
Herpes zoster D-4	1	1	0
Raynaud's	1	0	1
Mycosis fungoides	1	0	1

TABLE V
DATA OF 270 WRISTS OF PATIENTS WITH CARPAL-TUNNEL SYNDROME TREATED BY INJECTIONS

No. of Injections	Total	No Further Symptoms	Improvement (Without Operation)			Incomplete Follow-up	Operation Performed
			Moderate	Much	None		
1	141	27	17	10	15	39	33
2	54	13	14	10	2	7	8
3	32	8	5	3	2	5	9
4	20	2	7	1	2	2	6
5	8	2	1	1	1	1	2
6	5	0	3	1	0	1	0
7	3	0	3	0	0	0	0
9	2	0	0	0	0	0	2
10	2	0	2	0	0	0	0
11	3	0	3	0	0	0	0
Total	270	52	55	26	22	55	60

carpal-tunnel syndrome, the exact nature of which is not known. Many patients offer the information that their parents or grandparents had similar complaints, especially thenar atrophy. One patient in this series sought medical treatment only because she noticed slight atrophy of her right thenar muscles and feared that these muscles might waste away completely as did those of her mother.

Rheumatic conditions of various types about the wrist and hand are more common in women than in men. This fact may account for the much higher incidence of carpal-tunnel syndrome in women. In this series ninety-six patients had some form of associated tenosynovial disorder such as de Quervain's disease, trigger finger, and the like (Table IV).

In addition forty-nine patients were diagnosed as having rheumatoid arthritis, and four, as having lupus erythematosus.

The changes in the median nerve observed at operation shed little light on the pathogenesis of this syndrome. A bulbous swelling of the nerve proximal to the upper edge of the transverse carpal ligament—a so-called false neuroma—was observed in forty-five wrists. This finding was not associated with any pathological or anatomical abnormality in the extremity in thirty-three. In the other twelve, associated abnormalities were de Quervain's disease in three, peri-arthritis of the shoulder in two, and diabetes, tennis elbow, healed Colles' fracture, an ununited fracture of the carpal navicular, a ganglion, a synovial cyst with myxomatous degeneration, and trigger finger in one each. There was nothing to suggest that a false neuroma was a specific factor in the pathogenesis of the syndrome or that formation of the neuroma was related to any specific anatomical or pathological variation.

Obvious compression of the nerve characterized by flattening, thinning, and narrowing of the nerve beneath the transverse carpal ligament or by a transverse groove in the nerve at the level of the proximal edge of the ligament was found in 151 (71 per cent) of the 212 wrists treated surgically. In the other sixty-one wrists, the nerve was not deformed and there was no gross evidence of compression.

An acute carpal-tunnel syndrome, requiring immediate surgical decompression, was not encountered in this series. A hematoma in the palm, acute thrombosis of a persistent median artery, or an acute suppurative infection within the carpal tunnel might be expected to produce such a situation.

Treatment

Surgical treatment is not required for every patient with a carpal-tunnel syndrome. In this series only 177 patients (40 per cent of the entire group) had one or both hands operated on. Occasionally, a patient has such minor transient symptoms that no treatment whatsoever is indicated. It is obvious that resting the hands or a change of occupation is indicated for the patient who has had a recent onset of symptoms after an unusual amount of manual labor. Splinting the wrist in slight extension may be advisable for a week or two to enforce the necessary period of rest. Splinting of the wrist at night is indicated only in those persons who tend to sleep with their wrists sharply flexed and who are awakened by severe numbness and pain in the median-nerve distribution which can be reproduced by sustained wrist flexion.

The injection of hydrocortisone or some other steroid preparation into the carpal tunnel often gives excellent relief from the hypesthesia or paresthesia in the median distribution. Two hundred and seventy wrists (41 per cent) of the patients in this series were injected one or more times (Table V). The usual amount injected was one milliliter (twenty-five milligrams) of hydrocortisone tertiary-butylacetate or a similar amount of triamcinolone acetonide or methylprednisolone acetate. The injection is made through a 25-gauge needle inserted into the carpal tunnel, medial to the palmaris longus tendon and to the median nerve (Fig. 4). Care must be taken not to inject the steroid solution into the median nerve itself (Fig. 5), but rather to disperse the solution around the flexor tendons. The injection causes a little discomfort immediately, but the patient must be warned about the infrequent possibility of increased pain and swelling in the wrist and hand over the next twenty-four or forty-eight hours. An injection should be given no more frequently than every seven to ten days. If no improvement is obtained with the first injection, it is unlikely that further injections will help. One patient, a man eighty-two years old, received in the Department of Rheumatic Disease twenty-eight injections (seventeen in the left wrist and eleven in the right wrist) over a period of eight years. After the twenty-eighth injection in June 1963, a diagnosis of chemical neuritis involving the median

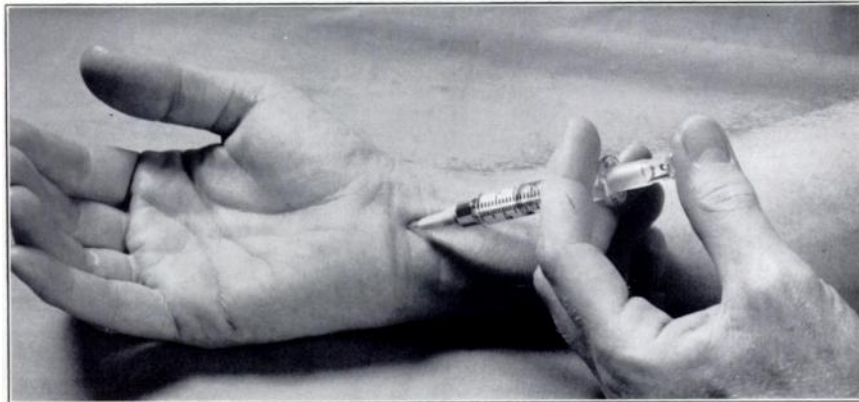


FIG. 4

The carpal tunnel is injected with one milliliter or less of hydrocortisone through a 25-gauge needle inserted just medial to the palmaris longus tendon. A local anesthetic is not necessary.

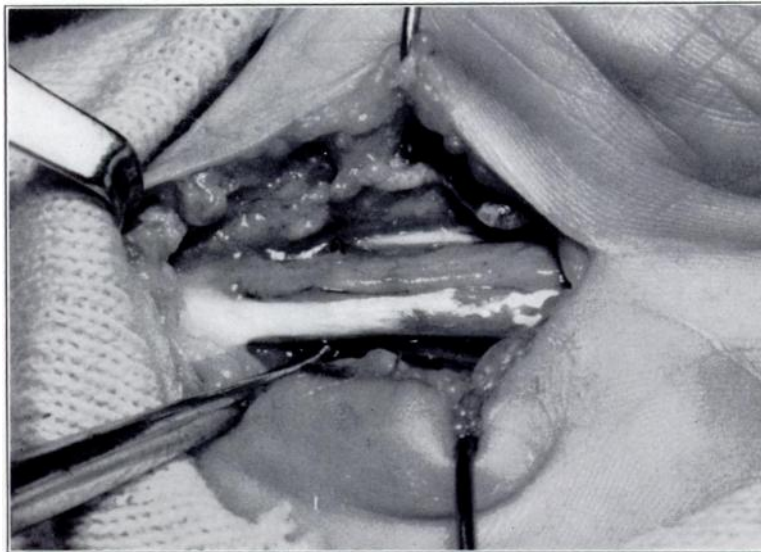


FIG. 5

Exposure of the median nerve in the carpal tunnel of a woman, sixty-four years old. A long-acting steroid preparation had been injected inadvertently into the median nerve one month before operation. Fortunately, the woman eventually had a good result.

nerve was made. Symptoms of this acute neuritis subsequently subsided leaving him with a positive Tinel sign over the median nerve at the wrist and paresthesias in the distribution of the median nerve in the hand. My preference is to give no more than three or four injections before advising surgical treatment. If thenar atrophy is present or if the patient's symptoms are of long duration, injections are seldom of value, and surgical treatment should be recommended immediately.

Prompt relief after injection of a steroid into the carpal tunnel gives additional support to the diagnosis of carpal-tunnel syndrome. The local effect of the steroid in reducing the swelling of the flexor synovialis is almost sure to produce some amelioration of the symptoms of median-nerve compression. Failure to obtain any improvement, however, does not indicate that the diagnosis of carpal-tunnel syndrome is in error.

Many of the patients in this series were given injections by members of the Department of Rheumatic Disease. Some patients received many injections. Of the 270

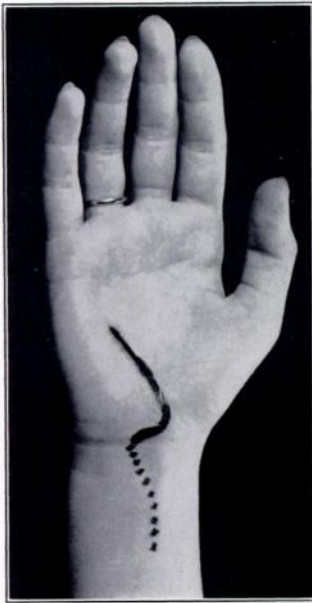

FIG. 6-A

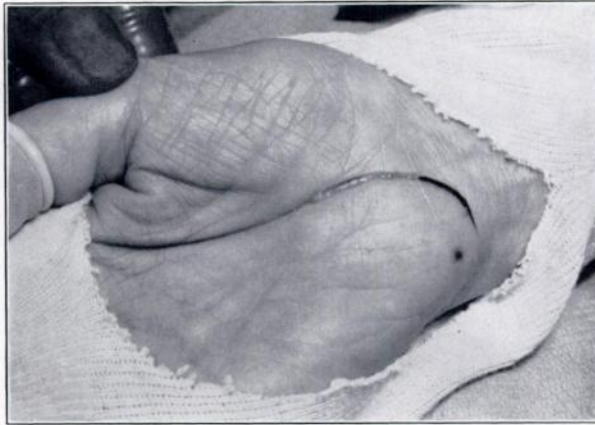

FIG. 6-B

Fig. 6-A: The carpal tunnel may be exposed by an oblique curved incision extending from the hypothenar eminence to the palmar crease. This incision may easily be extended across the wrist and up the volar aspect of the forearm if synovectomy is indicated.

Fig. 6-B: A similar incision may be used extending along the medial margin of the thenar eminence. Care must be taken to avoid injury to the recurrent branch of the median nerve.

wrists injected with a steroid preparation, sixty were eventually operated on (Table V). Fifty-two (24 per cent) of the wrists in the group gave no further symptoms after from one to five injections; eighty-one (38 per cent) showed some improvement, and twenty-two (10 per cent) were not improved. Recently I have been injecting the wrist of almost every patient with a carpal-tunnel syndrome at the time of the initial examination, provided, of course, there is no severe sensory deficit and no thenar atrophy that would require prompt surgical treatment. The injection does no harm if it is carefully performed; and, in early cases of carpal-tunnel syndrome, the prompt relief of paresthesia and night pain is greatly appreciated by the patient.

Sufficient decompression of the median nerve in the carpal tunnel is usually obtained by simply sectioning the entire transverse carpal ligament. This operation is readily performed with the aid of a pneumatic tourniquet under local anesthesia or regional perfusion anesthesia. The patient need not be hospitalized postoperatively. A pressure dressing is applied and is worn for three or four days; and the wrist is immobilized by a splint in neutral position for from seven to ten days or until the wound is healed.

Although most median nerves are compressed in the proximal third of the carpal tunnel, it is imperative that the entire transverse carpal ligament be severed. This may be carried out through a three-centimeter transverse incision in the distal flexion crease at the wrist, but the disadvantage of this approach is that the most distal portion of the ligament must be cut blindly. The ligament should be sectioned through its medial portion to avoid any possible damage to the recurrent branch of the median nerve. After section of the transverse carpal ligament there should be sufficient room in the carpal tunnel to permit a curved Kelly hemostat to slide easily into the palm or to allow the moistened little finger of the surgeon to pass readily along with the median nerve into the palm.

The entire roof of the carpal tunnel may be easily exposed through an oblique incision extending from the hypothenar eminence laterally across the base of the palm to the distal flexion crease at the wrist (Fig. 6-A). A similar incision may also be employed, extending from the thenar eminence medially across the base of the palm to the distal flexion crease of the wrist (Fig. 6-B). With these incisions,

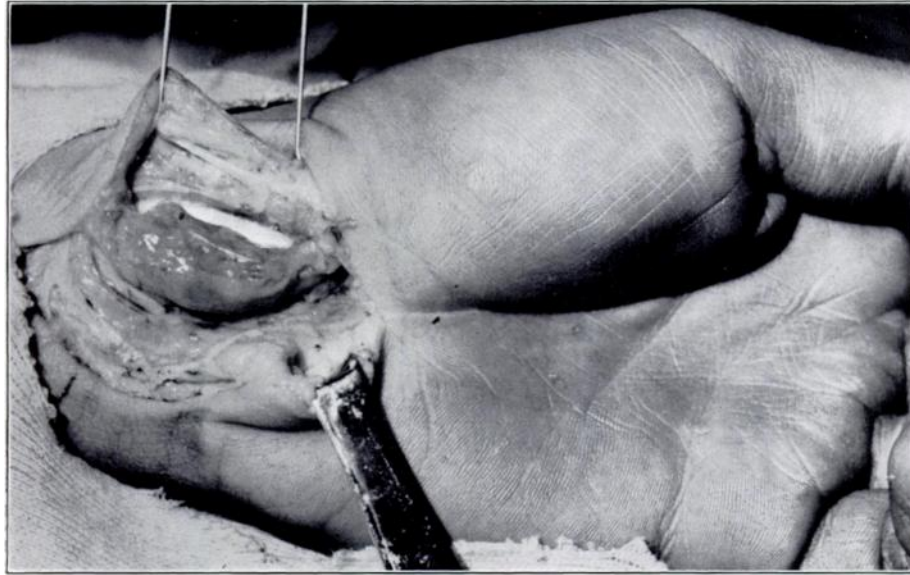


FIG. 7

Chronic inflammation of the flexor synovialis caused a carpal-tunnel syndrome in this man's wrist. Synovectomy was necessary to obtain adequate decompression of the median nerve in the carpal tunnel. The thickened synovial membrane is seen around the flexor pollicis longus tendon; the median nerve is displaced medially.

excellent exposure of the entire carpal tunnel to direct vision is obtained and the entire transverse carpal ligament may be readily divided and a portion excised, if desired. If further exploration of the median nerve or a synovectomy is indicated, either of these incisions may be prolonged as an S-shaped incision up the volar aspect of the forearm. Synovectomy cannot be done easily under local anesthesia alone. In this series fifty-eight hands were operated on under local anesthesia and 154 under general anesthesia. My present preference is to do more of these operations under local anaesthesia.

When the transverse carpal ligament is sectioned, the cut edges of the ligament separate about one-quarter of an inch. If after section of the ligament, the median nerve is not completely decompressed, then partial synovectomy of the flexor synovialis should be performed (Fig. 7). Usually the need for synovectomy may be anticipated when there is swelling on the volar aspect of the forearm proximal to the volar carpal ligament. If there is any possibility that synovectomy may be necessary, the transverse incision should not be used. Although a transverse incision may be prolonged by a gently curved proximal extension of one end and careful elevation of the skin flap, the circulation of the resultant flap is precarious and ischemia of the tip of the flap may ensue. In the 212 hands operated on in this series, synovectomy was necessary in eight (4 per cent). Routine synovectomy is not advisable, since this additional procedure prolongs the postoperative disability and may result in decreased excursion of the flexor tendons.

Routine neurolysis of the median nerve is also inadvisable, since even in long-standing lesions the swelling of the nerve proximal to the transverse carpal ligament does not appear to be a true interstitial neuroma. In none of the wrists that I have operated on has the enlargement of the nerve to palpation had the firm feeling characteristic of a post-traumatic neuroma. The swelling, I believe, is the result of edema proximal to the point of compression.

Occasionally, after section of the transverse carpal ligament, the palmaris longus tendon will be found to lie quite snugly over the median nerve. If there is any

indication that the tendon may be pressing on the median nerve, one should not hesitate to cut or to remove a section of this tendon. The palmaris longus tendon was severed in twenty-one wrists in this series and all had satisfactory results. There was no instance in this series when failure to divide the palmaris longus was a cause of failure. However, in one patient with rheumatoid arthritis and persistent symptoms after operation done elsewhere, re-exploration revealed that the palmaris longus tendon was indenting the median nerve because of pressure caused by the marked swelling of the flexor synovialis. Synovectomy and resection of the palmaris longus tendon relieved symptoms in the wrist.

In a patient with carpal-tunnel syndrome, any degree of thenar atrophy is an absolute indication for surgery. Progression of the numbness and paresthesia in the fingers and thumb is also an indication for surgical intervention. Surgical treatment is also advised when the patient's symptoms are incapacitating or of long duration.

Results of Surgical Treatment

There are few operations that are as successful and rewarding as the operation for carpal-tunnel syndrome.

In this study a follow-up period of less than five months was considered inadequate to determine the efficacy of treatment. I re-examined many of the patients and many others were contacted by letter or by telephone. Only twelve of the 177 surgically treated patients (thirteen of 212 hands) were followed for less than five months. Many patients had been followed for more than ten years. Fifteen wrists were operated on by other members of the Department of Orthopedic Surgery, and I performed the remaining 197 operations.

Of the patients surgically treated, both wrists were involved in ninety-nine, the right wrist only in fifty-three, and the left wrist only in twenty-five.

Of the ninety-nine patients with bilateral involvement thirty-eight had operation on both wrists; forty-five on the right wrist only, and sixteen on the left wrist only. When both wrists required surgical treatment, one wrist was operated on at a sitting unless the patient insisted on having both done at the same procedure. Bilateral operation was performed on ten patients, all of whom were considerably incapacitated for at least two days after operation, because with both extremities elevated to prevent edema, use of their hands was restricted. Of the sixty-one patients with bilateral symptoms who had operation on only one side, all were right-handed, except for one who was ambidextrous and had operation on the left side.

Of the fifty-three patients with right-sided involvement and operation on the right wrist, all were right-handed. Of the twenty-five with left-sided involvement and operation on the left side, only two were left-handed.

Thenar Atrophy

Thenar atrophy of greater or lesser degree was present in 120 (56 per cent) of the 212 hands operated on. Eight of these 120 hands with atrophy were either lost to follow-up or were followed for less than five months. Of the remaining 112 hands, seventy-six regained normal or almost normal thenar muscles between six and twelve months after operation; sixteen showed various degrees of improvement in thenar muscle power; twenty showed no improvement, but there was no progression of thenar atrophy, except in one hand.

No clear-cut explanation for the lack of thenar muscle recovery in twenty hands was apparent. The appearance of the nerve at operation in these hands was not remarkable. Twelve had neuromata, but these were no more severe than the neuromata of the patients who had no atrophy or whose atrophy disappeared after operation; the other eight nerves were not remarkable when they were exposed.

In the hand with progression of atrophy after operation re-exploration revealed incomplete severance of the distal portion of the transverse carpal ligament after the first operation which had been performed through a transverse incision at the wrist.

There was also no correlation between the duration of symptoms and postoperative disappearance of atrophy.

As a rule, the shorter the duration of thenar paralysis the quicker the recovery of muscle function. However, the duration of thenar atrophy was often difficult to establish, since many patients were not aware that their hands had any atrophy until their attention was called to this finding at the time of the initial examination. Furthermore, atrophy was rarely the initial symptom of the syndrome, and the onset of the atrophy was always gradual. Of the twenty hands that showed no postoperative improvement in thenar muscle power, seven were known to have had atrophy for more than twenty years; two, for more than ten years; five, for more than two years; and six, for one year or less. No firm prognosis in regard to the return of the thenar muscle power is possible. Formerly I believed that if the paralysis had existed for more than one year, the outlook for recovery after decompression of the median nerve was poor. I now know that thenar atrophy may exist for at least three years and still be relieved by section of the transverse carpal ligament. In one woman in this series who maintained that she had had atrophy of the thenar muscles for ten years, the atrophy had cleared up completely seventeen months after operation. At least nine patients had atrophy for three years or longer, and all regained thenar muscle power postoperatively.

Hypesthesia without Thenar Atrophy

Of the ninety-two hands surgically treated without thenar atrophy four (four patients) were lost to follow-up. Of the remaining eighty-eight hands, sixty-nine obtained excellent results from operation, with return of normal sensation and function; seventeen were improved but still had some impairment of sensation in the distribution of the median nerve; and two (two patients) were not improved. One of the hands not improved was that of a diabetic patient in whom a reflex sympathetic dystrophy developed and then gradually improved after many months. In the other hand showing no improvement in sensation one year after operation, there was some diminution of the preoperative burning pain in the palm.

As in the case of thenar atrophy there was no correlation between the postoperative improvement and the duration of symptoms or the operative findings.

Hypesthesia with Thenar Atrophy

Of the 112 adequately followed surgically treated hands with thenar atrophy and diminished sensation, eighty-five regained normal sensation postoperatively, twenty-three were improved but still had some impaired sensation in the median-nerve distribution, and four hands in four patients were not improved. Of these four patients, one, nine years after operation, had regained most of the thenar-muscle power and had no pain in the hand but still had the same mild sensory impairment that was present before operation; the second, eighty-three years old, showed no improvement at seven months; the third, eight months after operation, no longer had the night pain and forearm pain that she had had before operation, but her preoperative median hypesthesia remained unchanged; and the fourth, with only a six-month follow-up, had no relief of symptoms. No reason for the failure of surgery in these four patients was apparent.

Reoperations

Two hands were operated on a second time—one as previously noted, because

of progression of thenar atrophy, the other because of recurrence of numbness in the median-nerve distribution. The first patient was found to have incomplete severance of the distal portion of the transverse carpal ligament after the first operation which was performed through a transverse incision at the wrist. After the second operation, she regained normal sensation, muscle power, and function; her hand remained normal during the fifteen years that she has been followed.

The second patient had a re-exploration of the carpal tunnel nearly three years after the first procedure when repair of a spontaneous rupture of the extensor pollicis longus tendon was performed. At exploration scar tissue was found surrounding the median nerve. Lysis of the nerve and removal of scar tissue, combined with the tendon repair, restored normal motion of the thumb and resulted in some sensory improvement, although slight hypesthesia in the median distribution of the hand persisted. There was no apparent explanation for the excessive scarring. The patient had an old ununited fracture of the carpal scaphoid sustained twenty-eight years before re-exploration, but nothing was found at operation to suggest that this non-union had contributed to the scarring. There was no history of infection after the first operation and no evidence of rheumatoid arthritis.

When recommending an operation for carpal-tunnel syndrome, the surgeon may be quite confident that his patient will be relieved of pain in the median-nerve distribution; but, if the sensory loss is profound and of many years' duration, the patient must be advised that normal sensation in the hand will not necessarily be restored.

Complications

In the 212 hands operated on, there were no serious postoperative complications. In one man, some redness and induration developed about the incision but there was no drainage and the result was satisfactory. There were no other postoperative infections. The previously mentioned woman with diabetes, in whom a postoperative sympathetic dystrophy developed, eventually recovered almost completely. When last seen she had slight loss of motion in the proximal interphalangeal joints but no pain, muscle atrophy, or hypesthesia.

There were fourteen patients who underwent surgery for the carpal-tunnel syndrome elsewhere after they were examined and diagnosed at the Cleveland Clinic. Ten of these patients obtained good results. One patient noted only slight improvement and two patients were unimproved. The remaining patient was a practicing neurologist, who after consultation at the Cleveland Clinic, returned to his office and performed an operation on his own wrist under local anesthesia. He managed to sever a portion of the transverse carpal ligament, enough to relieve his pain but not enough to prevent progressive thenar atrophy.

Summary

At the Cleveland Clinic the diagnosis of carpal-tunnel syndrome has been made in 654 hands of 439 patients during the last seventeen years. The typical patient with this syndrome is a middle-aged housewife with numbness and tingling in the thumb and index, long, and ring fingers, which is worse at night and worse after excessive activity of the hands. The sensory disturbances, both objective and subjective, must be directly related to the sensory distribution of the median nerve distal to the wrist; but pain may be referred proximal to the wrist as high as the shoulder. There is usually a positive Tinel sign over the median nerve at the wrist, and the wrist-flexion test I described is also usually positive. About half of the patients also have some degree of thenar atrophy.

If steroid injections into the carpal tunnel give only transient relief, treatment

should be by complete section of the transverse carpal ligament. This procedure will almost always relieve the patient's pain and numbness in the hand, and in many cases will also cure the paralysis of the thenar muscles, which may be present.

References

1. BRAIN, W. R.; WRIGHT, A. D.; and WILKINSON, MARCIA: Spontaneous Compression of Both Median Nerves in the Carpal Tunnel. Six Cases Treated Surgically. *Lancet*, **1**: 277-282, 1947.
2. CANNON, B. W., and LOVE, J. G.: Tardy Median Palsy: Median Neuritis: Median Thenar Neuritis Amenable to Surgery. *Surgery*, **20**: 210-216, 1946.
3. GILLIATT, R. W., and WILSON, T. G.: A Pneumatic-Tourniquet Test in the Carpal-Tunnel Syndrome. *Lancet*, **2**: 595-597, 1953.
4. GROKOST, A. W., and DEMARTINI, F. E.: Systemic Disease and Carpal Tunnel Syndrome. *J. Am. Med. Assn.*, **155**: 635-637, 1954.
5. GROSSMAN, L. A.; KAPLAN, H. J.; OWNBY, F. D.; and GROSSMAN, M.: Carpal Tunnel Syndrome—Initial Manifestation of Systemic Disease. *J. Am. Med. Assn.*, **176**: 259-261, 1961.
6. JOHNSON, E. W.; WELLS, R. M.; and DURAN, R. J.: Diagnosis of Carpal Tunnel Syndrome. *Arch. Phys. Med. and Rehab.*, **43**: 414-419, 1962.
7. KREMER, MICHAEL; GILLIATT, R. W.; GOLDING, J. S. R.; and WILSON, T. G.: Acroparaesthesiae in Carpal-Tunnel Syndrome. *Lancet*, **2**: 590-595, 1953.
8. MARIE, PIERRE, and FOIX: Atrophie isolée de l'éminence thénar d'origine névritique. Rôle du ligament annulaire antérieur du carpe dans la pathogénie de la lésion. *Rev. Neurol.*, **26**: 647-649, 1913.
9. MOERSCH, F. P.: Median Thenar Neuritis. *Proc. Staff Meet. Mayo Clin.*, **13**: 220-222, 1938.
10. PAGET, JAMES: *Lectures on Surgical Pathology*. Philadelphia, Lindsay and Blakiston, 1854.
11. PHALEN, G. S.; GARDNER, W. J.; and LALONDE, A. A.: Neuropathy of the Median Nerve Due to Compression Beneath the Transverse Carpal Ligament. *J. Bone and Joint Surg.*, **32-A**: 109-112, Jan. 1950.
12. PHALEN, G. S.: Spontaneous Compression of the Median Nerve at the Wrist. *J. Am. Med. Assn.*, **145**: 1128-1132, 1951.
13. PHALEN, G. S., and KENDRICK, J. I.: Compression Neuropathy of the Median Nerve in the Carpal Tunnel. *J. Am. Med. Assn.*, **164**: 524-530, 1957.
14. REID, S. F.: Tenovaginitis Stenosans at the Carpal Tunnel. *Australian and New Zealand J. Surg.*, **25**: 204-213, 1956.
15. SCHILLER, FRANCIS, and KOLB, F. O.: Carpal Tunnel Syndrome in Acromegaly. *Neurology*, **4**: 271-282, 1954.
16. TANZER, R. C.: The Carpal-Tunnel Syndrome. A Clinical and Anatomical Study. *J. Bone and Joint Surg.*, **41-A**: 626-634, June 1959.